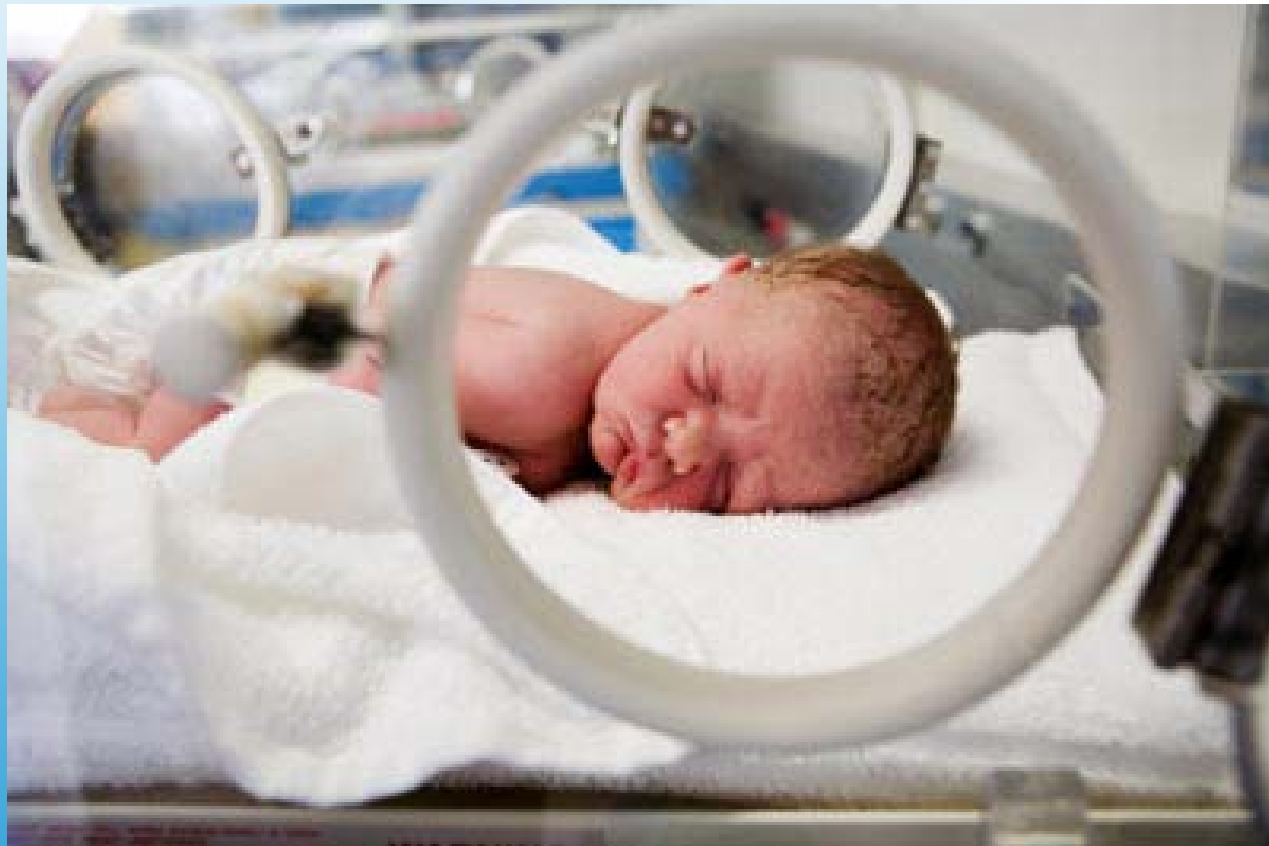



Mobile NICU Radiography

– How to Get Diagnostic Chest & Abdomen Images

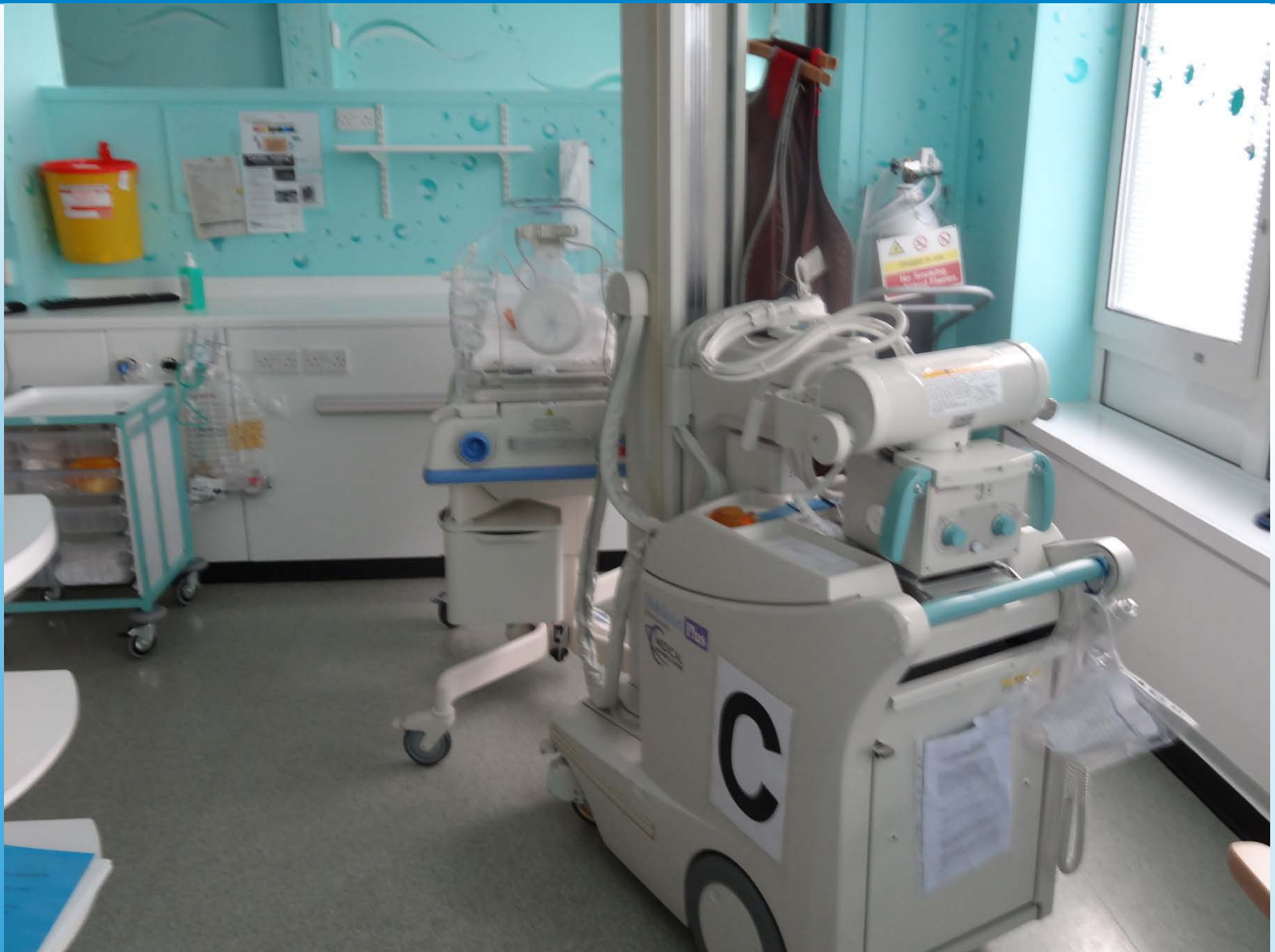- Identify baby according to IRME(R)/Local Rules
- Ensure that everything (including hands) that goes into incubator or cot is clean



At The Start



**Ensure Holding Person is Protected
& Not Pregnant**



Park Mobile at an Angle to Base of Incubator

- Lordosis
- Exposure
- Collimation
 - Rotation
- Respiration

Look **E**xcellent **C**hest **R**adiography **R**esults

Remember These Points in the Order
Shown...



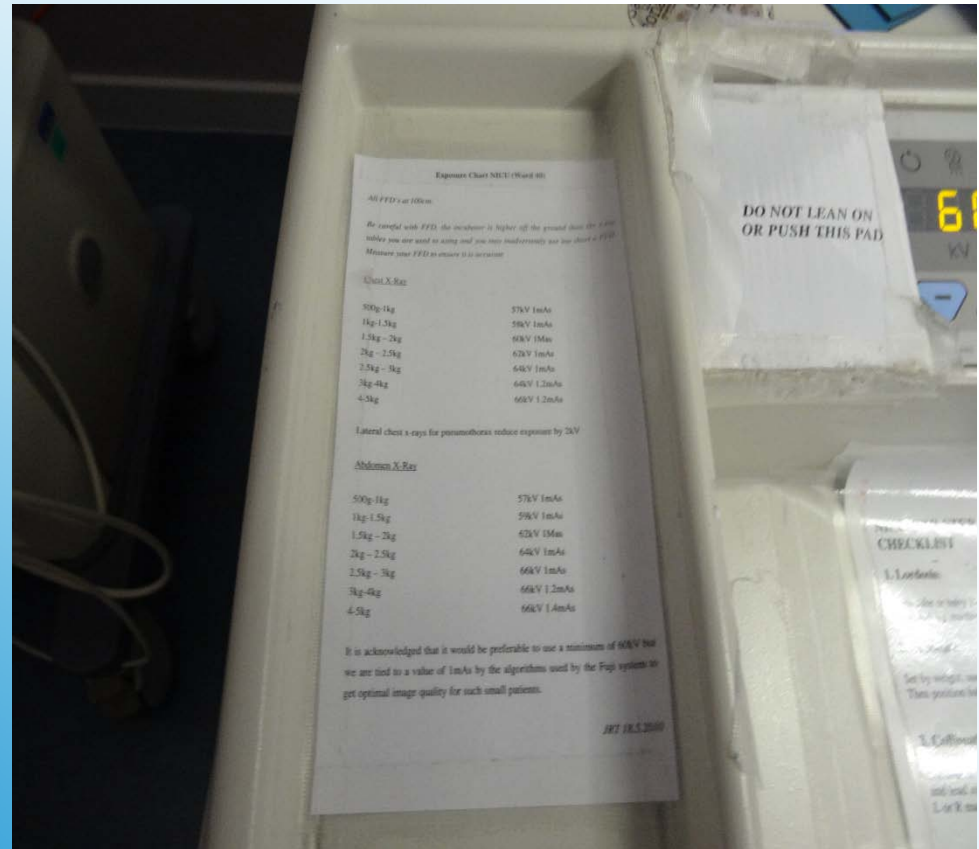
L = Lordosis: Position X-Ray Tube Now – Note the 10° Caudal Tube Angle as Baby is Flat

Key Points

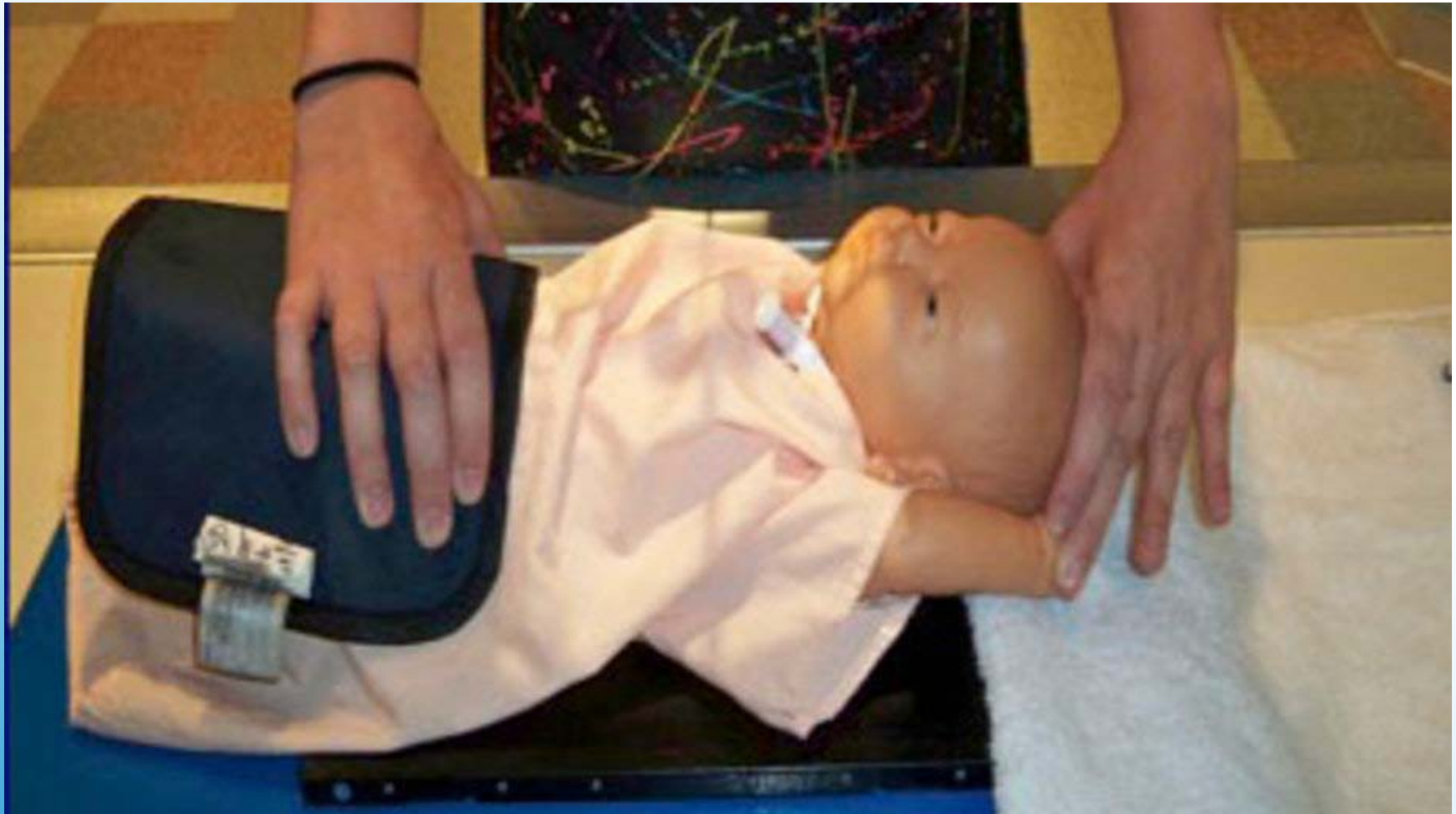- Baby should never be perpendicular to the central beam. Something should be angled 10° :
 - Either tube is angled caudally if baby is flat
- Or if baby is angled (head up) around 10° on the incubator tray, then use a a straight tube
- Either is equally good, just angle something or you will get a lordotic image

More About Lordosis

- Set exposure now before you start positioning so you do not forget later
- Ideally you should have a locally drawn up exposure chart on the mobile machine
- Be aware that the weight written on the card on the incubator might be out of date (this is the birth weight) – babies put on weight fast



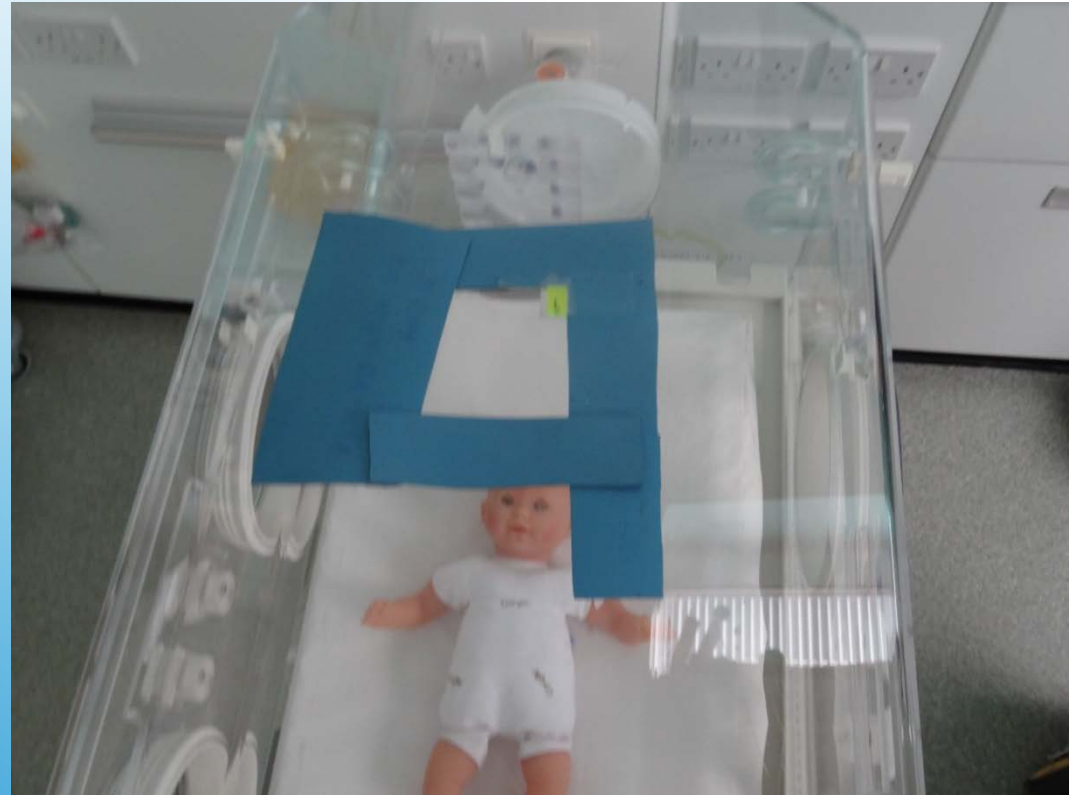E - Exposure



<https://www.nytimes.com/2011/02/28/health/28radiation.html>

**Position the Image Plate Now:
Centre to the Middle of the Sternum**

- Collimate as tightly as possible using the collimator blades
- Place lead strips on top of incubator as shown to provide a secondary layer of protection
- Ensure a side marker on the L-shaped strip is included and the side marker is included in the field over the shoulder



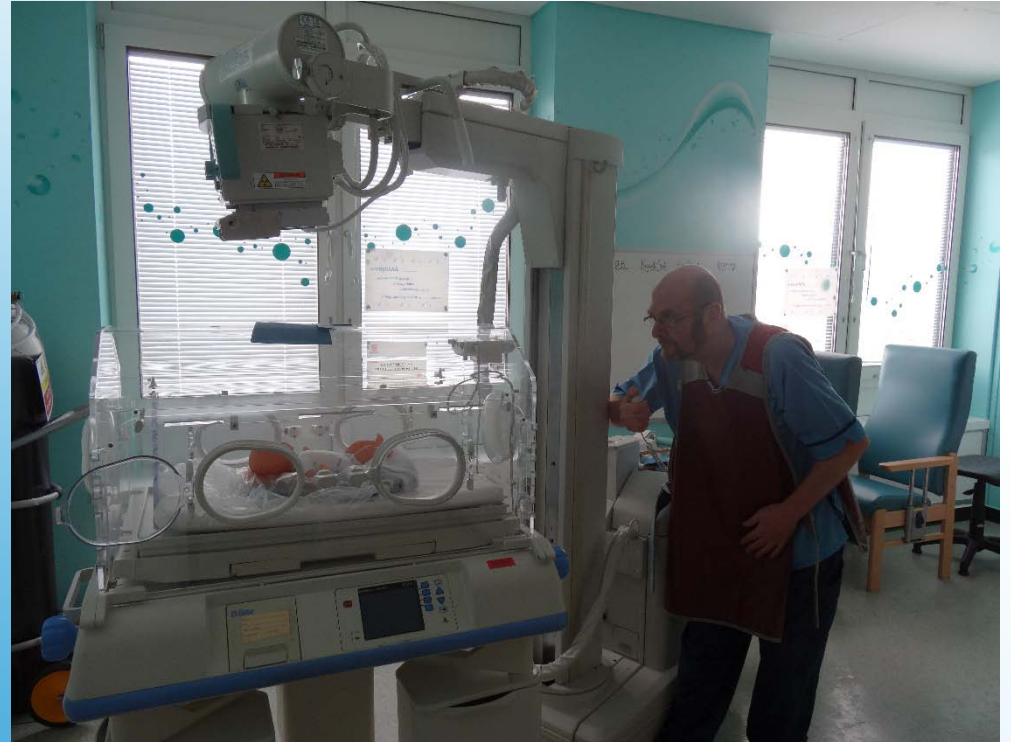C - Collimation



- Nurse should hold baby's head in AP position. Hips and shoulders parallel to image plate
- Baby's arms lying by sides but angled away from body if possible
- Baby's legs supported - e.g. by small towel

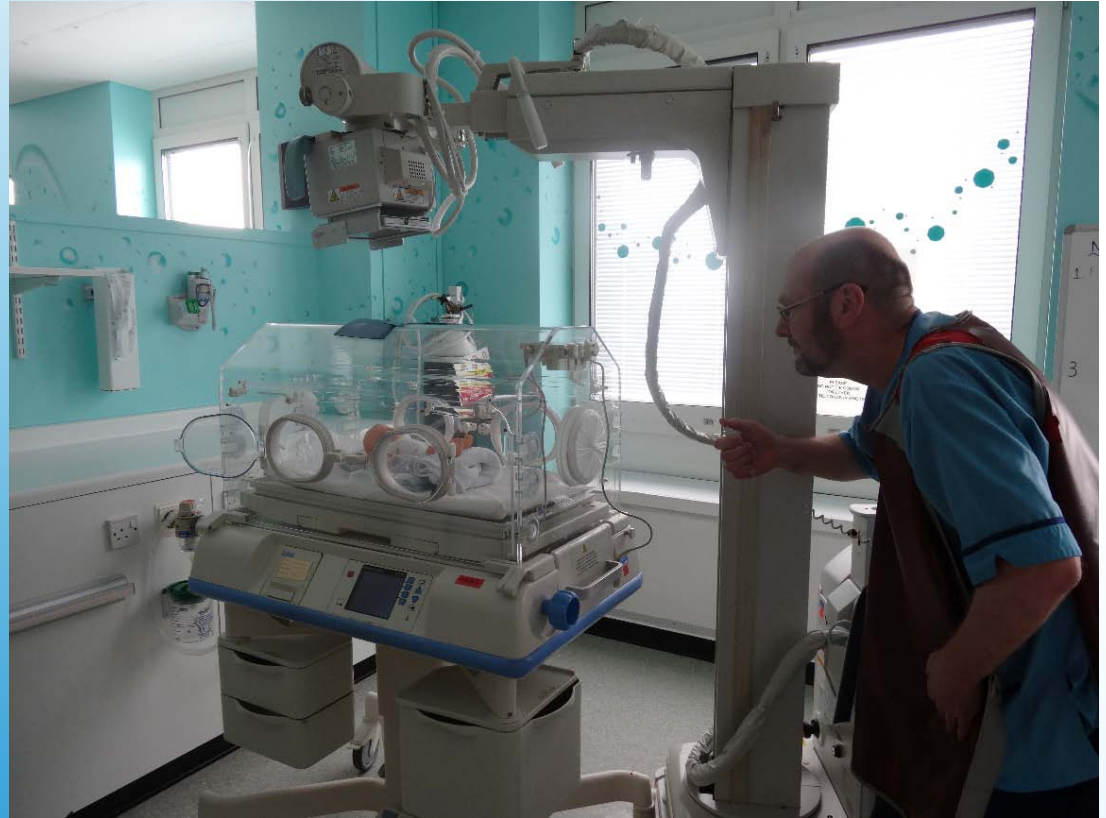R - Rotation (1)

- Radiographer must stand at bottom of incubator when exposing (nowhere else) – allows easier assessment of rotation
- Note again the caudal angle of the x-ray tube
- Note the concentration at time of exposure

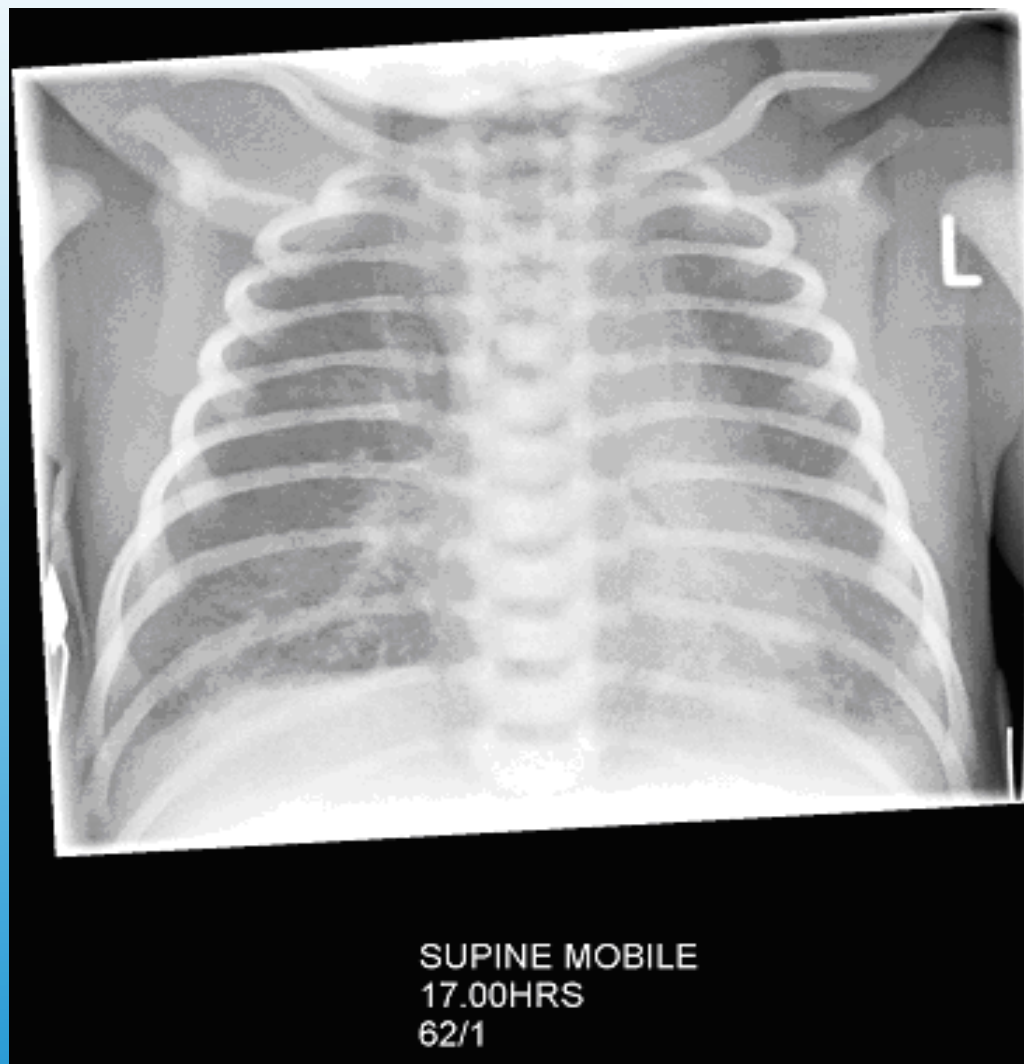


R – Rotation (2)

- Radiographer watches baby's breathing closely
- Baby is a tummy breather – when tummy is pushed out, lungs are full
- Expose when tummy is pushed out
- Counting 1-2-3 might help
- If baby is wriggling, wait a minute - baby might settle



R - Respiration



Simples

Why are they bad?

Alters heart shape and size

Causes mediastinal distortion

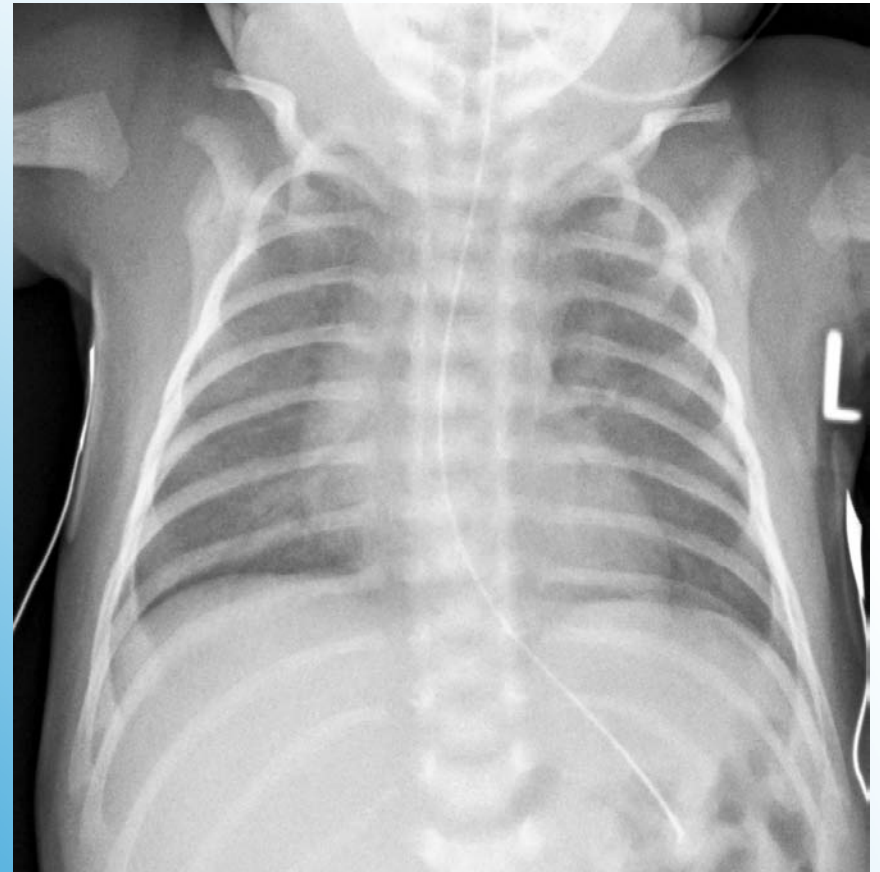
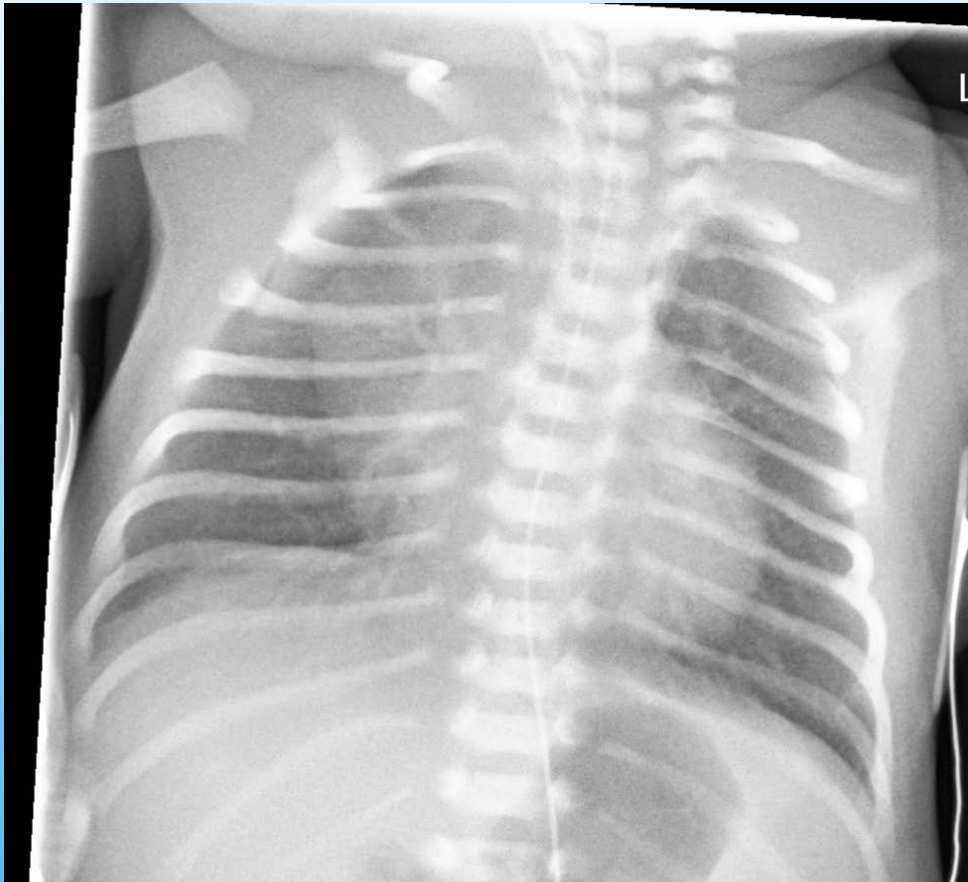
Shows differences in the degree of lung translucency

To avoid:

Ensure head is straight

Ensure shoulders and hips are level

Rotated Images



**Rotated image on left shows ?abnormal right lung mass.
Straight Image on right shows that the mass has
disappeared - it was the thymus gland**

Why are they bad?

Alters heart shape

Causes lower lobes of lungs to be masked by diaphragms

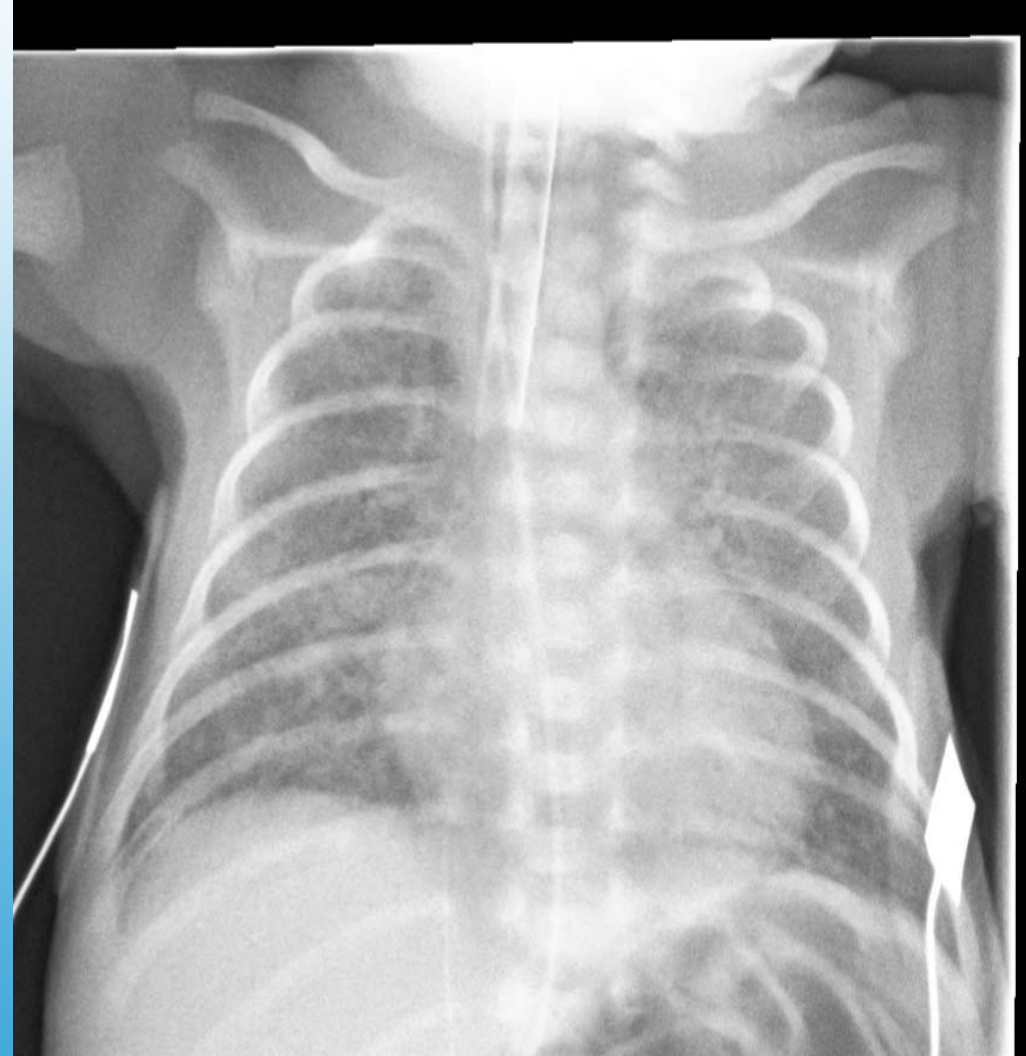
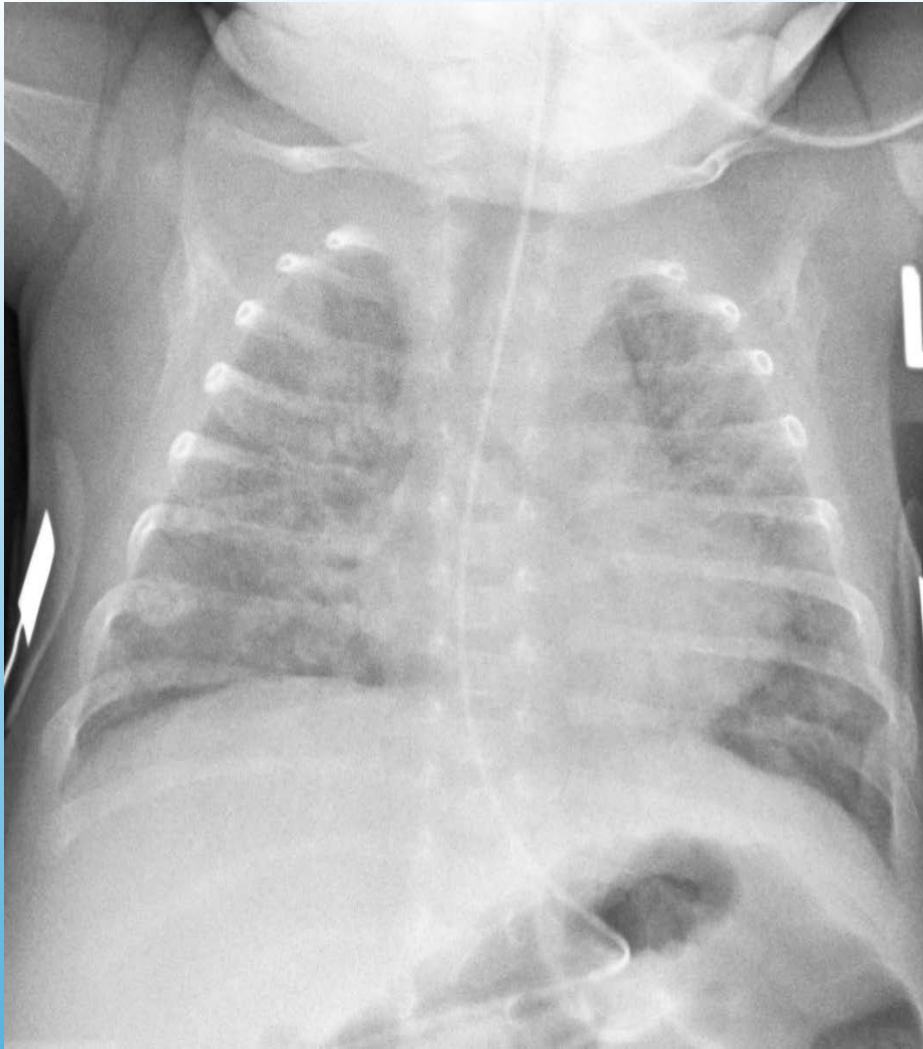To Avoid:

Don't centre too low -
centre to mid-sternum

Do not have central ray at
 90° to the image plate,
angle tube or tray

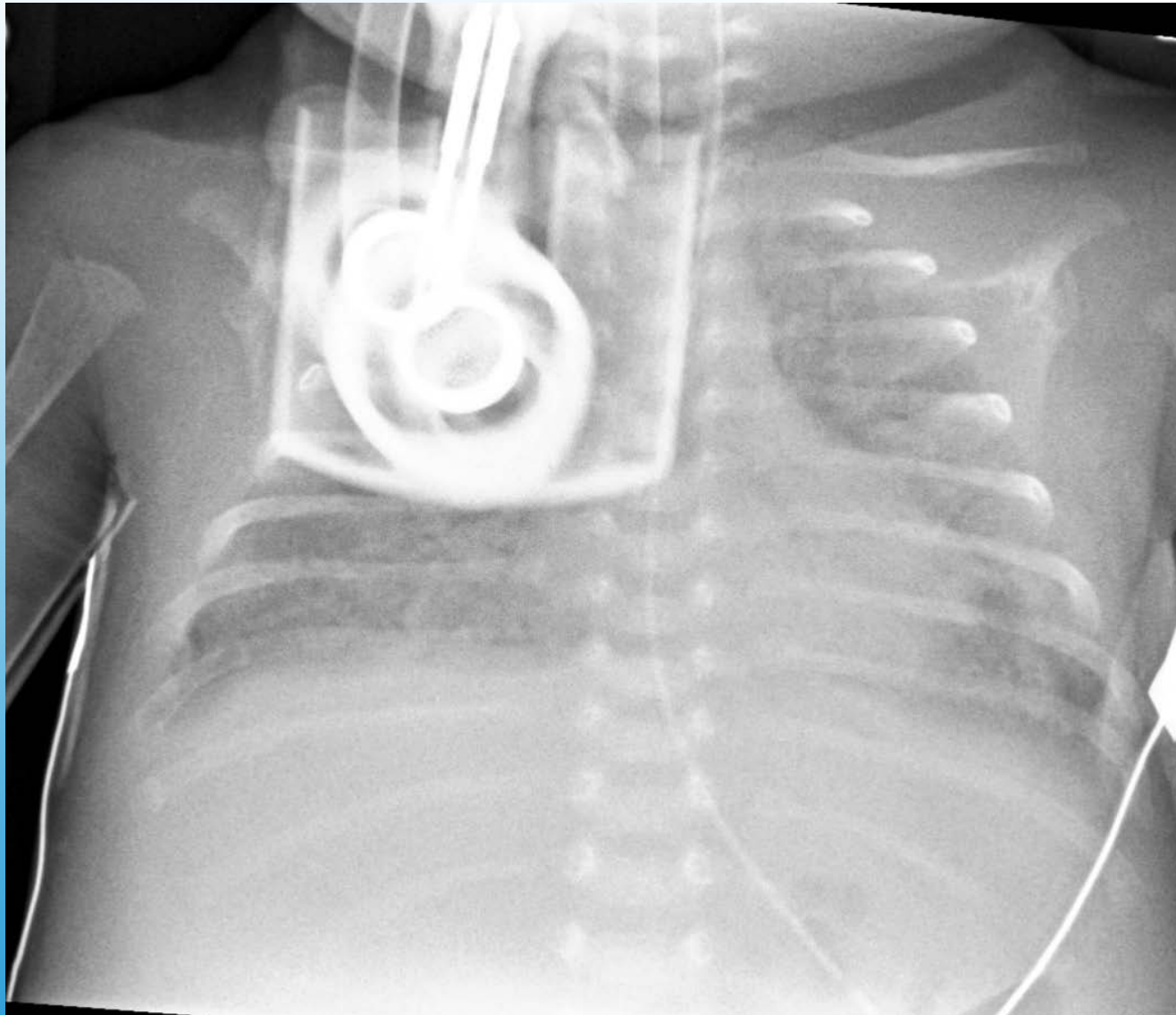
Be aware that holding
baby arms above head
can cause back to arch

Lordotic Images

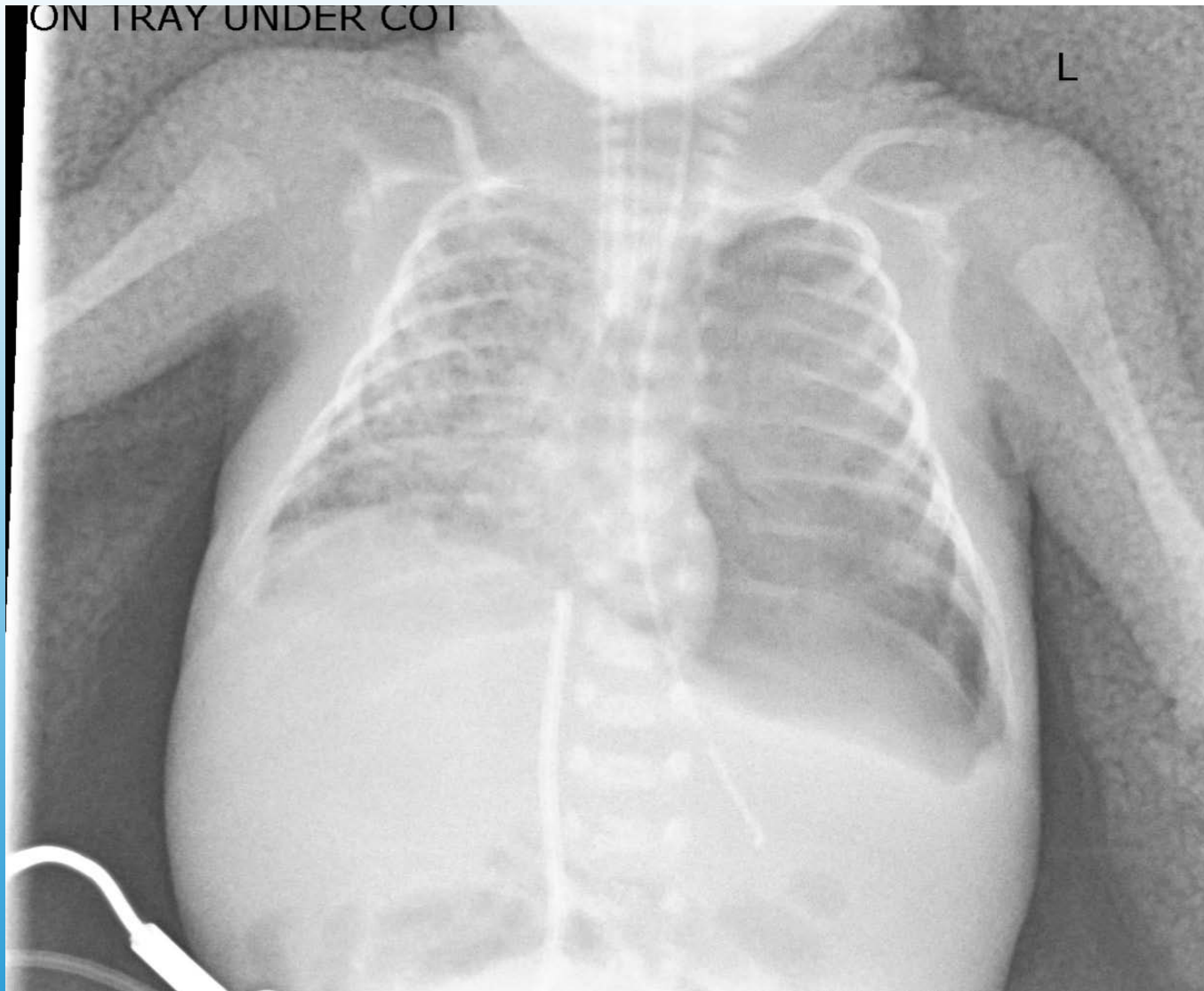

Lordotic Images

Note how the heart shape changes and the lower lung lobes are hidden on the lordotic image on the left

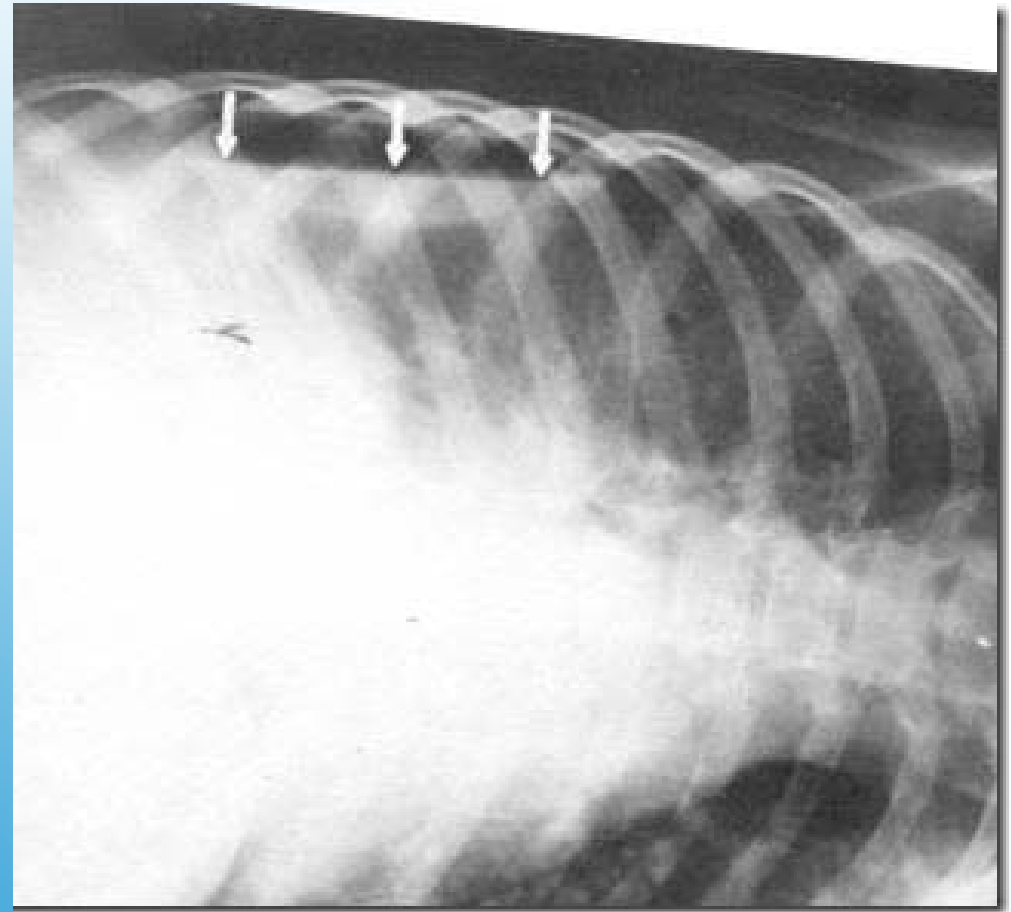


Ventilator Tubing Must Be Clear of Chest

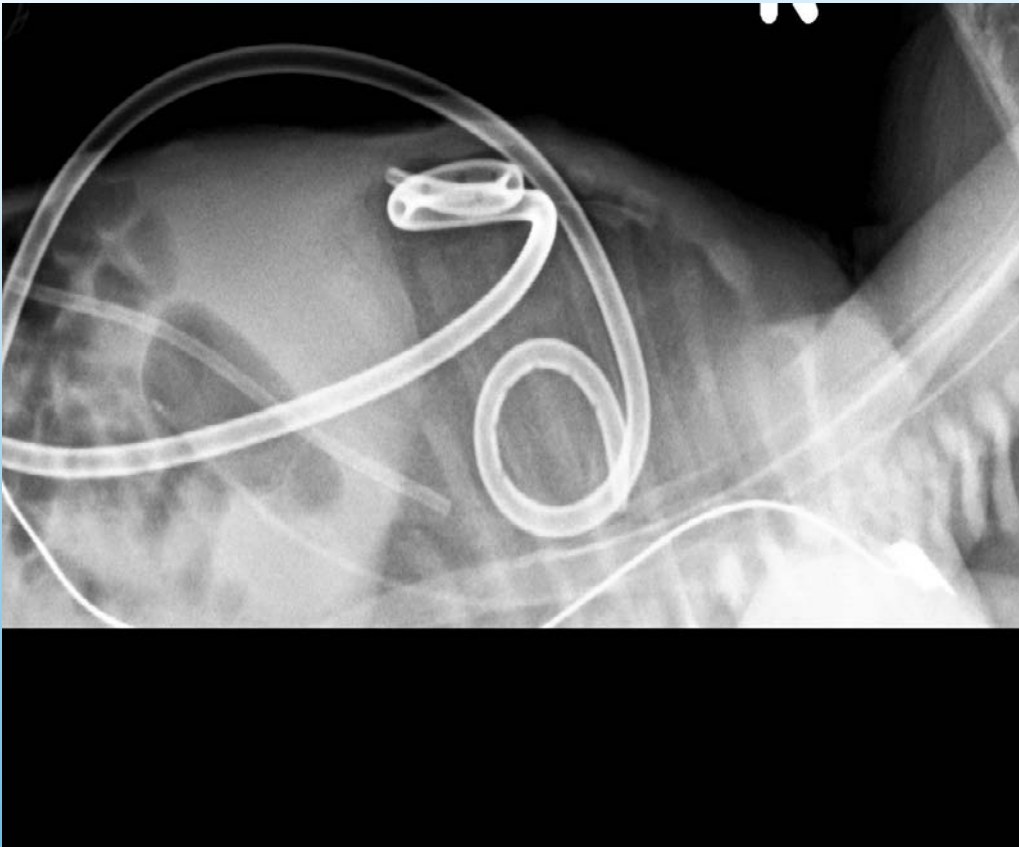


**Be Careful Using Cassette Trays -
Note the Artefact caused by Bedding**

- Position baby lying on a foam pad facing the x-ray tube
- Holding person holds head and arms with one hand and lower limbs with the other
- Suspicious side up but clinician will usually advise which they wish
- Beware of skin folds

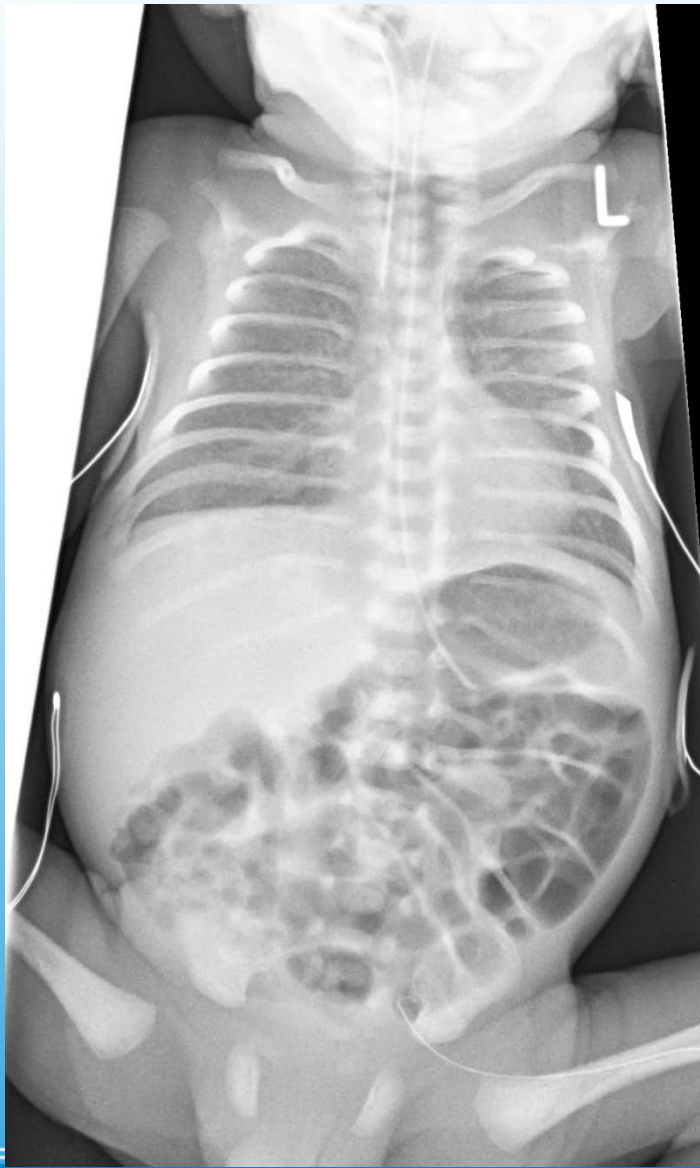

Lateral Decubitus Chest



- Again Horizontal Beam is Used
- Baby Lies Supine
- Baby Held With Arms Raised as Shown
- Reduce Exposure by Around 4kV!!!

Supine Decubitus Chest

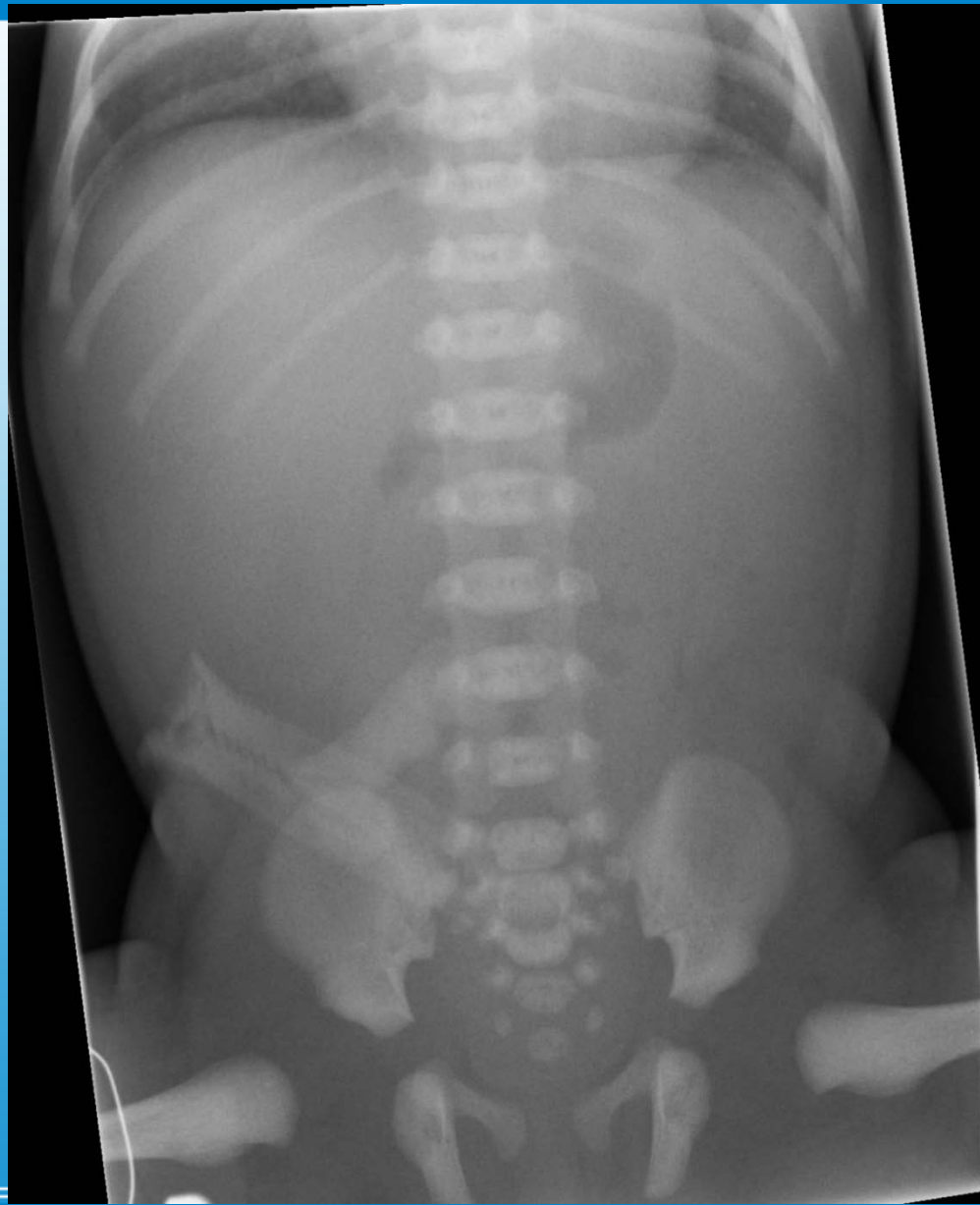

- Note the ECG leads are all moved to the lateral chest and abdomen walls
- Note also the “rugby-ball” shape of baby – be careful not to overcollimate the diaphragm area laterally

Chest & Abdomen 1 Image

- Baby to be held straight as for chest x-ray
 - Knees slightly bent
 - Centre just superior to the umbilicus
- Ensure excellent collimation and lead strip placement on incubator
- A small right side marker can be attached to the L-shaped lead strip so that it lies over the right inguinal area
- Remember that baby is a “rugby ball”

Abdomen Positioning



Supine Abdomen

Exposure 64kV , 1mAs , 100cm , 1cGy cm^2

Distance From Tube	Time to Receive Equiv. Background Dose
50cm	42 mins
1m	11 mins
2m	3 mins
3m	1 min
8m	11 secs

This information was kindly provided by Shellagh Neil, Medical Physicist, Ninewells Hospital (2009) to allay the fears of the NICU staff regarding holding neonates during imaging

Scattered Radiation

Further Reading...

Radiography of Children: A Guide to Good Practice

Judith Hardwick & Catherine Gyll

El Sevier 2004

The Supine Mobile Neonatal Chest X-Ray Made Easy (Well Almost)

John Temple

Imaging & Therapy Practice December 2014

- Audit your NICU/SCBU imaging
- Involve NICU/SCBU staff in any training
- All new radiographers starting at Ninewells Hospital are shown this PowerPoint and undergo practical training with a mobile unit, baby mannequin and incubator
- I am happy to give advice and tutorials

johnntemple@nhs.net



And finally...